

Subclavian artery dissection: a rare complication of transradial coronary angiography

Ersan Tatli, Murat Aksoy, M. Türker Pabuccu

Department of Cardiology, School of Medicine, Sakarya University, Sakarya, Turkey

Submitted: 30 June 2016

Accepted: 10 July 2016

Arch Med Sci Atheroscler Dis 2016; 1: 66–67

DOI: 10.5114/amsad.2016.61466

Copyright © 2016 Termedia & Banach

Corresponding author:

Ersan Tatli

Department of Cardiology

School of Medicine

Sakarya University

Sakarya, Turkey

Phone: 0505 678 90 99

Fax: 0 264 211 16 12

E-mail: ersantatli@yahoo.com

A 52-year-old female patient presenting with typical angina pectoris was admitted to the cardiac catheterization laboratory with evidence of inferior left ventricular wall ischemia detected by single photon emission computed tomography (SPECT) myocardial perfusion scintigraphy. A short, 6 Fr sheath was inserted into the right radial artery and a 5 Fr radial diagnostic catheter (Optitorque; Terumo Corporation) and 0.035-inch 260 cm “J” tip wire were used for diagnostic coronary angiography. While the guidewire was advanced to reach the ascending aorta, resistance was felt on the right subclavian artery. The guidewire was withdrawn and a selective right subclavian angiogram was performed; it demonstrated dissection of the right subclavian artery (Figure 1). The patient complained of moderate pain in the right clavicular region.

The J wire and radial diagnostic catheter were then exchanged for a 0.035-inch, 150 cm angled Glidewire (Terumo) and a 6 Fr right Judkins guiding catheter to advance into the true lumen under fluoroscopy. A “Y” connector was used and a Glidewire was carefully advanced through the true lumen, confirmed by subclavian angiography. The dissection segments were crossed with the guiding catheter, which was held in place at the level of the ascending aorta for at least 10 min (Figure 2). The guiding catheter and guidewire provided mechanical compression. After obtaining the final angiography displaying the complete sealing of the dissection, the procedure was accomplished by the same access without a need for cross-over (Figure 3). Coronary angiography showed patent left main and left descending coronary arteries, and non-critical plaques in the right and left circumflex coronary arteries. The patient was symptom free and the procedure was completed uneventfully.

Transradial angiography (TRA) has been widely approved for diagnostic and interventional coronary procedures due to reduced vascular complication rates, shorter hospital stay and improved patient comfort compared with the transfemoral approach [1, 2]. Hematoma, perforation, pseudoaneurysm and arteriovenous fistula are rare complications of transradial angiography [3, 4].

Subclavian artery dissection (SAD) as a complication of TRA is very rarely seen. To the best of our knowledge SAD as a complication of TRA has been previously reported only twice in the literature [5, 6]. Advanced age, hypertension and anatomic variations, atherosclerotic arteries, and tortuosity are predisposing factors for this rarely seen complication. Forceful manipulation of the guidewire and catheters may also result in SAD [6]. In our case, dissection occurred during the advancement of the guidewire, although there was no forceful manipulation.

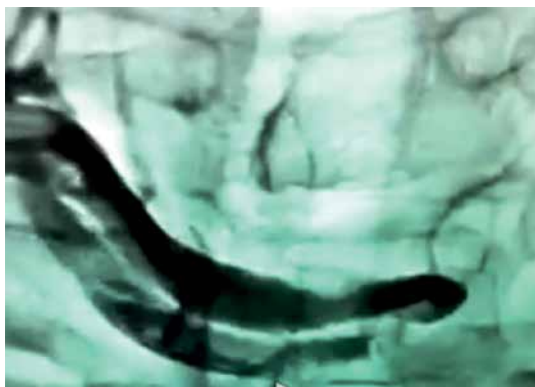


Figure 1. Subclavian artery dissection was shown on the subclavian angiography

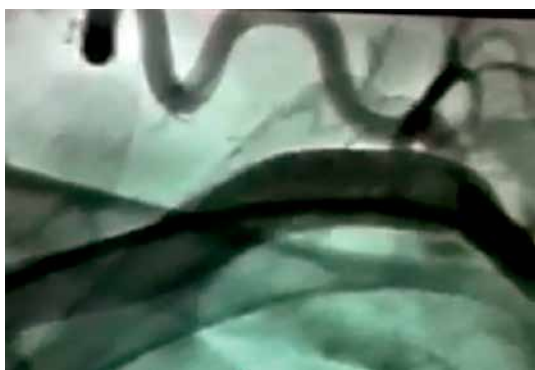

Figure 2. Guiding catheter and Glidewire were carefully advanced through the true lumen, confirmed by subclavian angiography

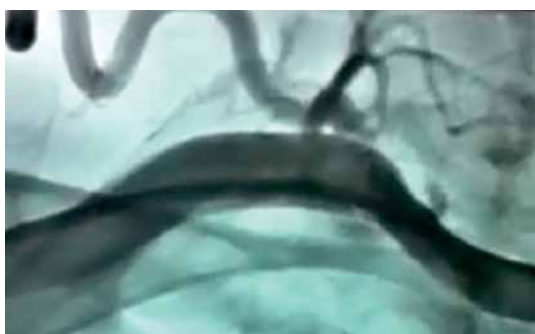

Figure 3. Final angiography displaying the complete sealing of the dissection

The presence of SAD should be suspected when there is resistance to the wire or catheter advancement, especially when the patient has a newly developed pain in the clavicular region. Early recognition of the SAD and treatment are of utmost importance to prevent acute hand ischemia. After the diagnosis, the dissected segment should be crossed by meticulous manipulation of 0.035 inch hydrophilic guidewires in the true lumen. We crossed the dissection with the 0.035 inch hydrophilic guidewire. The dissection segment is crossed with the guiding catheter, which is held in place at the level of the ascending aorta

for at least 5–20 min. The guiding catheter and guidewire provide mechanical compression. After obtaining the final angiography displaying the complete sealing of the dissection, the procedure is completed. This treatment is simple and permits the operator to continue the procedure. We treated the complication of our case with this technique. It should be kept in mind that the dissection that was caused by the guidewire or guiding catheter is a retrograde dissection, and most of the time it is not flow limiting and only requires conservative management.

In conclusion, subclavian artery dissection is a very rare complication of transradial coronary angiography. If subclavian artery dissection occurs, it can be managed and treated with this simple technique.

Conflict of interest

The authors declare no conflict of interest.

References

1. Louvard Y, Lefèvre T, Allain A, Morice M. Coronary angiography through the radial or the femoral approach: the CARAFE study. *Catheter Cardiovasc Interv* 2001; 52: 181-7.
2. Agostoni P, Biondi-Zoccai GG, de Benedictis ML, et al. Radial versus femoral approach for percutaneous coronary diagnostic and interventional procedures: systematic overview and meta-analysis of randomized trials. *J Am Coll Cardiol* 2004; 44: 349-56.
3. Tatli E, Buturak A, Cakar A, et al. Unusual vascular complications associated with transradial coronary procedures among 10,324 patients: case based experience and treatment options. *J Interv Cardiol* 2015; 28: 305-12.
4. Tatli E, Gunduz Y, Buturak A. Hematoma of the breast: a rare complication of transradial angiography and its treatment with handmade stent graft. *J Invasive Cardiol* 2014; 26: E24-6.
5. Trayer T, Sanghvi K. Complications of transradial catheterization: axillary and subclavian artery dissection. *Cath Lab Digest* 2013; 21: 11.
6. López-Palop R, Carrillo P, Frutos A, Cordero A. Conservative management of iatrogenic subclavian artery dissection during a percutaneous coronary interventional procedure. *Rev Esp Cardiol* 2011; 64: 833-4.