

Secondary aortoenteric fistula: a narrative review of the view of the surgeon

Francesk Mulita¹, Vasileios Leivaditis², Georgios-Ioannis Verras¹, Christos Pitros³, Platon Dimopoulos⁴, Paraskevi F. Katsakiori⁵, Danai Dafnomili¹, Levan Tchabashvili¹, Konstantinos Tasios¹, Dimitrios Kehagias¹, Andreas Antzoulas¹, Spyros Papadoulas³, Efstratios Koletsis⁶

¹Department of Surgery, General University Hospital of Patras, Patras, Greece

²Department of Cardiothoracic and Vascular Surgery, WestfalzKlinikum, Kaiserslautern, Germany

³Department of Vascular Surgery, General University Hospital of Patras, Patras, Greece

⁴Department of Interventional Radiology, General University Hospital of Patras, Patras, Greece

⁵Health Centre of Akrata, Akrata, Greece

⁶Department of Cardiothoracic Surgery, General University Hospital of Patras, Patras, Greece

Corresponding author:

Dr. Francesk Mulita
Department of Surgery
General University
Hospital of Patras
Patras, Greece
E-mail: oknarfmulita@
hotmail.com

Submitted: 31 January 2024; **Accepted:** 21 March 2024

Online publication: 30 March 2024

Arch Med Sci Atheroscler Dis 2024; 9; e66–e71

DOI: <https://doi.org/10.5114/amsad/186358>

Copyright © 2024 Termedia & Banach

Abstract

Aortoenteric fistula (AEF) is defined as the abnormal communication between the aorta and the gastrointestinal tract. AEFs are divided into primary and secondary usually after abdominal aortic aneurysm (AAA) recovery and are a rare but quite dangerous cause of gastrointestinal bleeding that the general surgeon may face during his/her career. Secondary AEF was first described in 1953 to a 44-year-old woman 3 months after an AAA operation. This review presents the role of the surgeon in the management of secondary aortoenteric fistulas. AEFs are a rare but fatal gastrointestinal bleeding cause that the general surgeon may be asked to manage. Diagnosis requires the combination of strong clinical suspicion and the presence of a history of AAA surgery. Although a vascular surgery case, general surgeons play a role in choosing the technique of restoring the intestinal tract, which seems to be significantly related to subsequent morbidity and mortality.

Key words: aortoenteric fistula, abdominal aortic aneurysm, aorta, secondary.

Introduction

Aortoenteric fistulas were first described by Cooper [1] as a complication of abdominal aortic aneurysms, while the first case is described in 1843 by Salmon [2] and defined as the abnormal communication between the aorta and the gastrointestinal tract. Aortoenteric fistulas are divided into primary and secondary usually after abdominal aortic aneurysm recovery and are a rare but quite dangerous cause of gastrointestinal bleeding that the general surgeon may face during his/her career. Secondary aortoenteric fistula (SAEF) was first described by Brock in 1953 in the case of a 44-year-old woman 3 months after AAA operation [3]. This review presents the role of the surgeon in the management of secondary aortoenteric fistulas.

The aim of our review is to provide a brief overview of a rare but potentially rapidly fatal condition that general surgeons worldwide might be called to face in the emergency setting. Although specialised management of this condition is paramount to the effective treatment of the SAEF, emergency presentations often require management and surgically-led stabilisation from the general surgeon that is not trained in vascular surgery.

We summarised, in a concise way, the knowledge deriving from the available literature about SAEFs, providing the surgeon’s view.

Material and methods

Studies were identified by searching electronic databases and scanning bibliographic references of articles. The National Library of Medicine’s Medline database was searched using the PubMed interface and Scopus from 1990 to 2023. No language constraints were used. The last search was run on 12 December 2023. Keywords were selected us-

ing medical subject headings (MeSH) for PubMed and MeSH/Emtree for Scopus. The keywords were “secondary fistula”, “aortoenteric”, “aortojejunal”, and “aortoiliac”. The databases were searched with an unrestricted search strategy, applying exploded MeSH and keywords combined with the Boolean operators AND or OR to retrieve relevant reports as reported in Table I. A second-level search included a manual screen of the reference lists of the articles identified through the electronic search. Eligibility assessment was performed independently in an unblinded, standardised manner by 2 reviewers; disagreements between reviewers were resolved by consensus (Figure 1).

Results

Epidemiology

SAEFs can occur after both open and intravascular reconstructive surgery for an aortic aneurysm or other aortic diseases with incidence rang-

Table I. The database search strategy

Search strategy	Results
Medline (PubMed)	
1 ((«neoplasm metastasis»[MeSH Terms] OR («neoplasm»[All Fields] AND «metastasis»[All Fields]) OR «neoplasm metastasis»[All Fields] OR «secondaries»[All Fields] OR «secondary»[MeSH Subheading] OR «secondary»[All Fields]) AND («fistula»[MeSH Terms] OR «fistula»[All Fields] OR «fistulas»[All Fields] OR «fistula s»[All Fields] OR «fistulae»[All Fields] OR «fistulaes»[All Fields])	10 727
2 («aortoenteric»[All Fields] OR «aortojejunal»[All Fields] OR «aortocolonic»[All Fields])	937
3 #1 AND #2	407
Scopus	
TITLE-ABS-KEY: secondary fistula AND (aortoenteric OR aortojejunal OR aortocolonic)	102

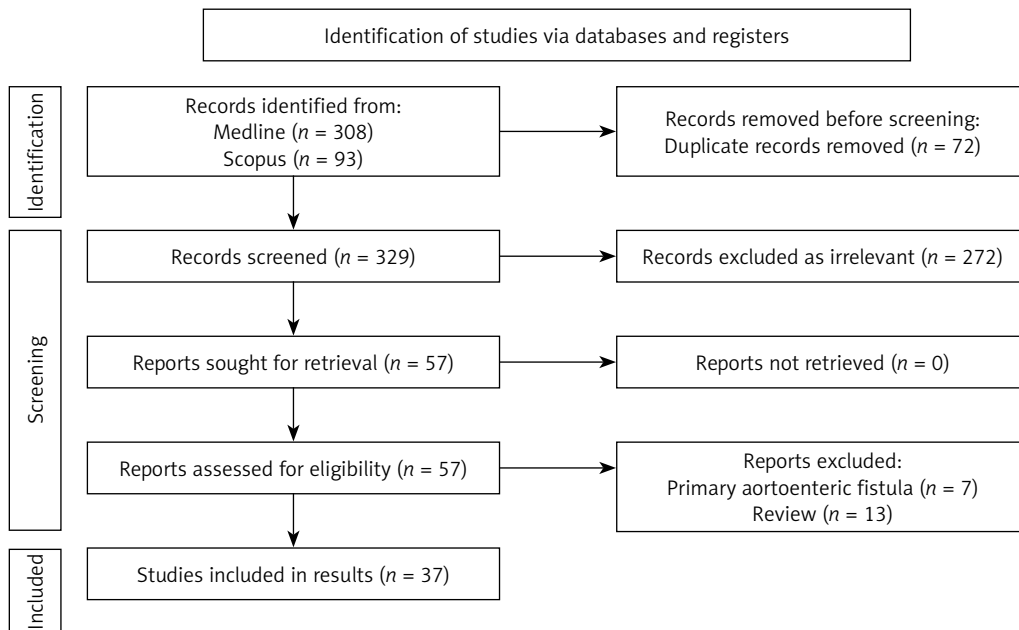


Figure 1. PRISMA Flow diagram. A list of included articles

ing from 0.36 to 1.6% and increasing to 12–33% in cases who have an infected graft [4, 5]. They are more common in adults, and the proportion of male to female is 8 : 1 [6, 7]. They usually occur within the first year after surgery (time range 1–20 years) [7, 8]. The mortality rate of SAEF has been reported to be up to 50–70% [9].

A recent series [10] demonstrated that SAEF continues to be a life-threatening condition, with a 27% in-hospital mortality rate, which is substantially higher upon emergency presentation, despite prompt diagnosis and treatment. The majority of fistulas involving the intestinal tract are between the aorta and the 3rd–4th portion of the duodenum (between the abdominal aorta and the superior mesenteric artery) in 74% of cases, followed by the small intestine (jejunum more commonly than the ileum) 19%, the colon 5%, and the appendix 1% [11–14].

Pathogenesis

The pathogenesis of SAEFs is not entirely clear although some hypotheses have been described. The main mechanism seems to be the gradual erosion of the aortic graft in the intestine, with or without the presence of inflammation from the intestinal contents. The constant irritation of the intestinal wall by the aortic pulsation seems to play an important role, which explains why most fistulas appear at the proximal anastomotic site of the third portion of the duodenum, which is pressed between the aorta and the superior mesenteric artery in the retroperitoneal space [3, 15–17]. Other hypotheses presuppose the presence of local inflammation and subsequent erosion of the intestinal wall due to infection of the aortic graft during the first operation [11, 15, 18–20]. A positive preoperative blood culture predicts a poor outcome [21, 22].

Clinical picture – diagnosis

The diagnosis of an aortoenteric fistula can become quite challenging, and strong clinical suspicion is required. Although the clinical picture is directly related to the part of the gastrointestinal tract where the fistula has formed, typically patients come with at least one of the following: gastrointestinal bleeding (melena, haematochezia, haematemesis) 80%, sepsis (44%), abdominal pain (30%), lumbar pain 15%, groin mass (12%), and abdominal pulsatile mass (6%). Other under-reported symptoms include acute limb ischaemia, pain, vomiting, ileus, and septic emboli to the legs [3, 5, 13]. The typical triad: gastrointestinal bleeding, abdominal pain, and palpable mass, is found in only 6–12% of cases [23]. Intermittent bleeding followed by massive bleeding (Herald bleeding) is typical for the disease and raises a strong suspicion of diagnosis although it occurs in approximately 60% [5, 18, 20, 24, 25]. Song *et al.* [26] proposed that the occurrence of herald bleeding had a mean frequency of 3.6 episodes. They also found that the time interval between the first herald bleeding and massive exsanguination varied from 5 h to 5 months, with a median of 4 days. More than 50% of cases had a duration longer than 3 days [26]. This time frame can be used as an opportunity for the treatment of fistulas [14].

For imaging, several methods have been proposed, the most useful being oesophagogastro-duodenoscopy and computed tomography (CT). The choice of imaging method depends on the patient's condition, the presence or not of bleeding, and its severity. In the case of massive bleeding, the patient should be taken directly to the operating room without further delay. In acute bleeding in stable patients, endoscopy is usually performed but with low accuracy in the diagnosis of

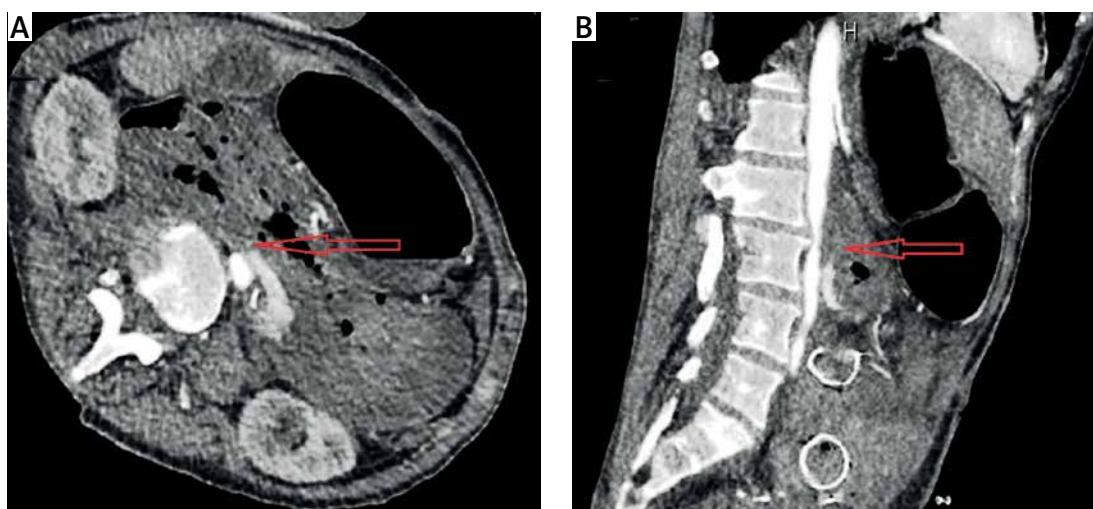

Figure 2. A – CT angiography showing the intravenous contrast extravasation in the lumen of the duodenum (red arrow). B – The migrated duodenal stent is also recognised (red arrow)

AEF (25–40%) [6, 26, 27]. As already mentioned, most aortoenteric fistulas are found in the 3rd-4th portion of the duodenum and for this reason the endoscope should reach the entire length of the duodenum, while use of an enteroscopy or paediatric endoscopes is recommended [6, 8, 28–30]. The presence of fresh blood and clots are indicative. Colonoscopy is not often cited as a diagnostic method [31, 32].

Spiral CT is fast and easily accessible from most centres. Intravenous contrast-enhanced CT helps both in the diagnosis and in the later decision of surgical repair of the aorta due to the anatomical information it provides [25, 33]. CT findings suggestive of AEF are air around the aorta, bowel wall oedema around the aorta, and the loss of a fatty plane between the aorta and GI tract (Figure 2). The fistula itself may not be visualised. CT angiography can be negative, despite an active bleed from an AEF [32]. Despite the great value of imaging, the clinical presence of gastrointestinal bleeding is very important for differentiating AEFs from other entities such as perigraft infection without fistulation.

Treatment

The treatment of SAEFs, regardless of their location, is exclusively surgical, and without it the mortality is 100%. With appropriate treatment, survival rates greatly varying between 18% and 93% have been reported [22, 34]. The choice of technique depends on the patient's condition, the severity of bleeding, comorbidities, and the presence or absence of inflammation. In the first phase, resuscitation and haemodynamic support are of

priority. Preoperative intravenous broad-spectrum antibiotic therapy for Gram+, Gram–, and enteric pathogens may be administered followed by targeted therapy [35].

The treatment of AEF includes graft excision and extra-anatomic bypass or *in situ* graft replacement and simple graft excision alone. Conservative or palliative treatment, utilising antibiotics and drainage or irrigation, is also acceptable for patients unfit for surgery [36]. Endovascular repair is a less invasive alternative, including limited reports for the treatment of AEFs. In SAEF, endovascular treatment (Figure 3) is performed as a bridging therapy to open repair to stabilise the patient until open repair is accessible. A recent multi-centre study [37] for the management of SAEFs found that there was no discernible distinction in all-cause mortality rates among patients who received EVAR or OAR as initial therapy for SAEF. In the acute setting, EVAR may be considered as a primary treatment or a bridge to definitive OAR in conjunction with broad-spectrum antimicrobial therapy for patients with SAEF. Kakkos *et al.* [13] came to conclusion that for SAEFs, endovascular surgery is associated with a higher early survival rate ($p < 0.001$) than open surgery, when appropriate, since in hospital mortality was 7.1% for endovascular surgery and 33.9% for open repair. Long-term follow-up erodes the majority of this benefit, because late sepsis occurred more often after endovascular surgery (2-year rate 42% vs. 19% for open, $p = 0.001$), suggesting that in certain patients, a staged approach with early conversion to *in situ* vein grafting may produce the best results. Open procedure (staged or not staged) has as its

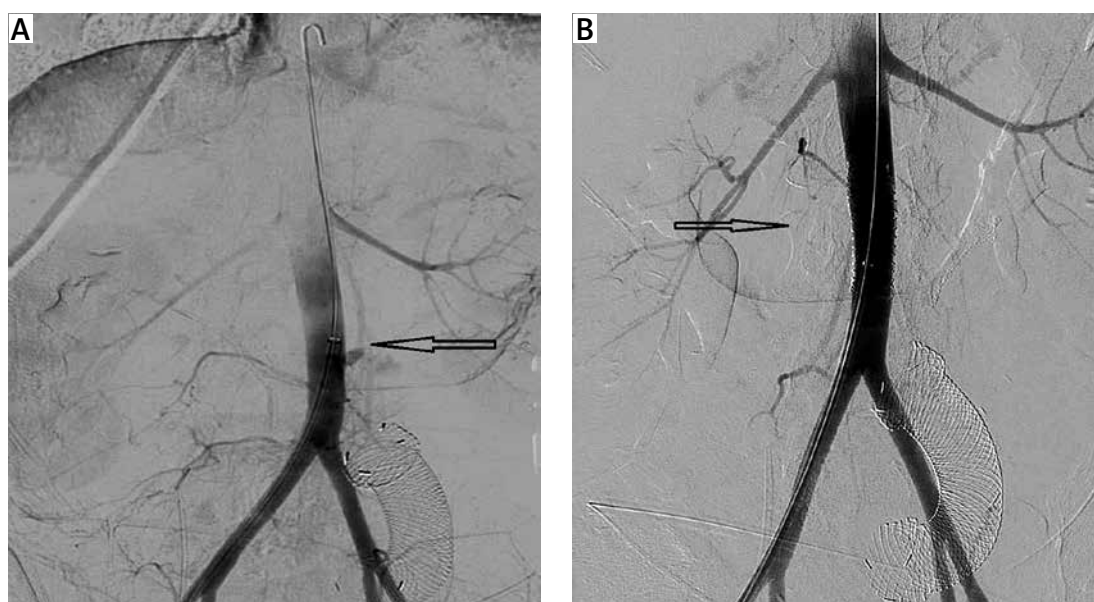


Figure 3. A, B – Extravasation of the IV contrast during the aortography and occlusion after the aortic stent placement (black arrows). The migrated duodenal stent is also recognised

fundamental objectives the confirmation of the diagnosis, the control of bleeding and inflammation, and the restoration of the continuity of the intestinal tract. Older series demonstrate operative mortality as high as 64% [38]. A recent study [39] provides the 20-year experience of a single centre, reporting significant improvement in 30-day ($p = 0.03$) and 90-day ($p = 0.008$) mortality even on risk-adjusted analysis, with no significant difference in 1-year survival overall.

The management of aortoduodenal fistulas has been studied more than the other subtypes of aortoenteric fistulas due to the frequency of occurrence. Initially, a laparotomy is conducted with temporary in situ revascularisation with a prosthetic graft, and later, a staged extra-anatomic bypass followed by transabdominal removal of the temporarily placed graft. Duodenal exclusion is not an obligatory adjunct to duodenal repairs, but in some cases resection of the fistula-bearing area of the aneurysm resected en bloc with the attached duodenum may be needed. In some cases extensive destruction of the duodenal wall is noted, and then pylorus-preserving pancreaticoduodenectomy is an option. A vascularised pedicle of the greater omentum can be used to wrap around the prosthetic graft or cover the infected surgical field for the purpose of preventing a graft infection. Aortojejunal fistula are rare and usually treated with primary repair, and the jejunal defect is closed using a linear stapler [40, 41]. Aortocolonic fistulas are better treated with some type of colectomy and/or transverse colostomy. In general, patients who undergo bowel resection have a worse prognosis than those who have simple repair [42]. Iliac-appendiceal fistula is a rare medical entity, which is treated with appendectomy and partial cecectomy [43].

Limitations: As a narrative review, our study has inherent limitations. Our study was done in a systematic way, but it is not a systematic review, and a significant risk of bias remains. Many of the data we have presented may derive from low-quality studies such as case reports. No statistical analysis was done to further interpret the collected data.

In conclusion, the role of the general surgeon in managing an aortoenteric fistula (AEF) is crucial and multifaceted. In short, it can be summarised in the points below:

- The surgeon must confirm the diagnosis of SAEF. This is often done through imaging techniques like computed tomography (CT), which provides superior images compared to other diagnostic modalities.
- One of the primary responsibilities of the surgeon is to control the bleeding associated with SAEF. This is particularly important because most AEFs are heralded by repetitive gastrointestinal bleeds

- The surgeon must repair the damaged area of the bowel
- If the condition is caused by an AAA or a previous aortic graft, the surgeon will need to remove the aneurysm or graft that is causing the issue
- Once SAEF is diagnosed, preventive measures, such as antibiotic therapy, delicate surgery for eradication of septic focus with thorough debridement of infected and devitalised tissue, and reconstruction of the excised aorta by extra-anatomic or an in situ route, are required
- Over time, operative mortality rates have decreased, possibly due to improvements in perioperative care and the advent of endovascular techniques

Aortoenteric fistulas are a rare but fatal gastrointestinal bleeding cause that the general surgeon may be asked to manage. Diagnosis requires the combination of strong clinical suspicion and the presence of a history of AAA surgery. Although a vascular surgery case, general surgeons play a role in choosing the technique of restoring the intestinal tract, which seems to be significantly related to subsequent morbidity and mortality.

Funding

No external funding.

Ethics approval

Not applicable.

Conflict of interest

The authors declare no conflict of interest.

References

1. Cooper, Astley, Sir 1768-1841, Tyrrell, Frederick 1793-1843. The Lectures of Sir Astley Cooper on the Principles and Practice of Surgery. 5th Americ. <http://resource.nlm.nih.gov/101561088>.
2. Salmon M. Aneurysme de l'aorte ventrale: most par rupture de la poche arterielle dans le duodenum. Bull Soc Anat 1843; 283: 18-28.
3. Bergqvist D, Björck M. Secondary arterioenteric fistulation – a systematic literature analysis. Eur J Vasc Endovasc Surg 2009; 37: 31-42.
4. Hallett JW, Marshall DM, Petterson TM, et al. Graft-related complications after abdominal aortic aneurysm repair: reassurance from a 36-year population-based experience. J Vasc Surg 1997; 25: 277-86.
5. Xiromeritis K, Dalainas I, Stamatakos M, Filis K. Aortoenteric fistulae: present-day management. Int Surg 2011; 96: 266-73.
6. Luo J, Tang W, Wang M, Xiao Y, Tan M, Jiang C. Case series of aortoenteric fistulas: a rare cause of gastrointestinal bleeding. BMC Gastroenterol 2021; 21: 49.
7. del Moral LR, Alonso SF, Kiuri SS, et al. Aortoenteric fistula arising as a complication of endovascular treatment of abdominal aortic aneurysm. Ann Vasc Surg 2009; 23: 255.e13-255.e17.

8. Batt M, Jean-Baptiste E, O'Connor S, et al. Early and late results of contemporary management of 37 secondary aortoenteric fistulae. *Eur J Vasc Endovasc Surg* 2011; 41: 748-57.
9. Bunt TJ. Synthetic vascular graft infections. II. Graft-enteric erosions and graft-enteric fistulas. *Surgery* 1983; 94: 1-9.
10. Sieber S, Busch A, Sargut M, et al. A modern series of secondary aortoenteric fistula – a 19-year experience. *Vasc Endovascular Surg* 2024; 58: 185-92. 3
11. Malik MU, Ucbilek E, Sherwal AS. Critical gastrointestinal bleed due to secondary aortoenteric fistula. *J Community Hosp Intern Med Perspect* 2015; 5: 29677.
12. Yagi M, Aiboshi J, Kojima M, et al. Life-saving case of cardiopulmonary arrest by secondary aortoenteric fistula formed in the anastomotic site between the inferior mesenteric artery and aortic graft. *Acute Med Surg* 2022; 9: e2744.
13. Kakkos SK, Bicknell CD, Tsolakis IA, Bergqvist D. Editor's choice – management of secondary aorto-enteric and other abdominal arterio-enteric fistulas: a review and pooled data analysis. *Eur J Vasc Endovasc Surg* 2016; 52: 770-86.
14. Kunioka S, Kitahara H, Ohira S, Tada Y, Akasaka N, Kamiya H. Surgical management of aortoenteric erosion due to pulsatile stress after aneurysm repair: a case report. *Ann Vasc Dis* 2020; 13: 355-7.
15. Armstrong PA, Back MR, Wilson JS, Shames ML, Johnson BL, Bandyk DF. Improved outcomes in the recent management of secondary aortoenteric fistula. *J Vasc Surg* 2005; 42: 660-6.
16. Saito H, Nishikawa Y, Akahira JI, et al. Secondary aortoenteric fistula possibly associated with continuous physical stimulation: a case report and review of the literature. *J Med Case Rep* 2019; 13: 61.
17. Chenu C, Marcheix B, Barcelo C, Rousseau H. Aorto-enteric fistula after endovascular abdominal aortic aneurysm repair: case report and review. *Eur J Vasc Endovasc Surg* 2009; 37: 401-6.
18. Lee SM, Lai YK, Wen WD. Aortoenteric fistula secondary to an inflammatory abdominal aortic aneurysm. *J Radiol Case Rep* 2019; 13: 8-27.
19. Takeda Y, Daimon M, Tsuji M, Katsumata T, Morita H, Ishizaka N. Repetitive complications after prosthetic graft for inflammatory aortic aneurysm. *SAGE Open Med Case Rep* 2013; 1: 2050313X1351323.
20. Deijen CL, Smulders YM, Coveliers HME, Wisselink W, Rauwerda JA, Hoksbergen AWJ. The importance of early diagnosis and treatment of patients with aortoenteric fistulas presenting with herald bleeds. *Ann Vasc Surg* 2016; 36: 28-34.
21. Peck JJ. Aortoenteric fistulas. *Arch Surg*. 1992; 127: 1191.
22. Cho YP, Kang GH, Han MS, et al. Staged surgery for chronic primary aortoduodenal fistula in a septic patient. *J Korean Med Sci* 2004; 19: 302-4.
23. Reilly LM, Ehrenfeld WK, Goldstone RJS. Gastrointestinal tract involvement by prosthetic graft infection. The significance of gastrointestinal hemorrhage. *Ann Surg* 1985; 202: 342-8.
24. Brahmabhatt P, Plemister J, Atia A, McKinney J, Schmidt L, Young M. Herald bleeding: a hidden catastrophe: 1478. *Am J Gastroenterol* 2013; 108: S438.
25. Kim JY, Kim YW, Kim CJ, Lim HI, Kim DL, Huh S. Successful surgical treatment of aortoenteric fistula. *J Korean Med Sci* 2007; 22: 846.
26. Song Y, Liu Q, Shen H, Jia X, Zhang H, Qiao L. Diagnosis and management of primary aortoenteric fistulas: experience learned from eighteen patients. *Surgery* 2008; 143: 43-50.
27. Saers SJF, Scheltinga MRM. Primary aortoenteric fistula. *Br J Surg* 2005; 92: 143-52.
28. Iwaki T, Miyatani H, Yoshida Y, Okochi T, Tanaka O, Adachi H. Secondary aortoduodenal fistula without gastrointestinal bleeding directly detected by CT and endoscopy. *Radiol Case Reports* 2012; 7: 774.
29. Gerson LB, Fidler JL, Cave DR, Leighton JA. ACG clinical guideline: diagnosis and management of small bowel bleeding. *Am J Gastroenterol* 2015; 110: 1265-87.
30. Senadhi V, Brown JC, Arora D, Shaffer R, Shetty D, Mackrell P. A mysterious cause of gastrointestinal bleeding disguising itself as diverticulosis and peptic ulcer disease: a review of diagnostic modalities for aortoenteric fistula. *Case Rep Gastroenterol* 2010; 4: 510-7.
31. Higgins JA, Margni M, Agko M, Nazzari M, Abbas J. Aortocolonic fistula: an interesting approach to a rare surgical complication. *Am Surg* 2011; 77: 804-6.
32. Davie M, Yung DE, Plevris JN, Koulaouzidis A. Case report: Aortoenteric fistula: a rare but critical cause of small bowel bleeding discovered on capsule endoscopy. *BMJ Case Rep* 2019; 12: 230083.
33. Lesèche G, Castier Y, Petit MD, et al. Long-term results of cryopreserved arterial allograft reconstruction in infected prosthetic grafts and mycotic aneurysms of the abdominal aorta. *J Vasc Surg* 2001; 34: 616-22.
34. Lemos DW, Rafferto JD, Moore TC, Menzoian JO. Primary aortoduodenal fistula: a case report and review of the literature. *J Vasc Surg* 2003; 37: 686-9. 1
35. Hansen BA, Amundsen S, Reikvam H, Wendelbo Ø, Pedersen G. Non-curative surgery for aortoenteric fistula. *J Surg Case Rep* 2017; 2017: rjx153.
36. Chakfé N, Diener H, Lejay A, et al. Editor's Choice - European Society for Vascular Surgery (ESVS) 2020 Clinical practice guidelines on the management of vascular graft and endograft infections. *Eur J Vasc Endovasc Surg* 2020; 59: 339-84.
37. Narayanan A, Hanna J, Okamura-Kho A, et al. Management of secondary aorto-enteric fistulae: a multi-centre study. *ANZ J Surg* 2023; 93: 2363-9.
38. Salo J, Verkkala K, Ketonen P, Harjola PT. Graft-enteric fistulas and erosions, complications of synthetic aortic grafting. *Vasc Endovasc Surg* 1986; 20: 88-93.
39. Bartley A, Scali ST, Patterson S, et al. Improved perioperative mortality after secondary aortoenteric fistula repair and lessons learned from a 20-year experience. *J Vasc Surg* 2022; 75: 287-95.e3.
40. Yoshimoto K, Shiiya N, Onodera Y, Yasuda K. Secondary aortoenteric fistula. *J Vasc Surg* 2005; 42: 805.
41. Zarbaliyev E, Konukoğlu O, Çağlıkülekcı M, Mansuroğlu D, Baş S, Kilercik H. Surgical approach to recurrent secondary aortoenteric fistulas: a case report. *Turk J Thorac Cardiovasc Surg* 2021; 29: 399.
42. Cendan JC, Thomas JB, Seeger JM. Twenty-one cases of aortoenteric fistula: lessons for the general surgeon. *Am Surg* 2004; 70: 583-7.
43. Gurien SD, Stright A, Garuthara M, Klein JDS, Rosca M. An iliac-appendiceal fistula causing gastrointestinal bleeding. *J Vasc Surg Cases Innov Tech* 2019; 5: 107-9.