

Cathepsin L in unstable plaques

Ayisha Z. Bashir

Doctoral student, Department of Biomechanics, University of Nebraska, Omaha, USA

Submitted: 16 February 2020

Accepted: 18 April 2020

Arch Med Sci Atheroscler Dis 2020; 5: e57–e63
DOI: <https://doi.org/10.5114/amsad.2020.95563>
Copyright © 2020 Termedia & Banach

Corresponding author:

Ayisha Bashir MBBS, MS
Department of Biomechanics
University of Nebraska
Omaha, USA
Phone: 402-740-7394
E-mail: abashir@unomaha.edu

Bridging the gap between the pathogenesis of atherosclerosis, carotid plaques, and contributing to patient care is envisioned by incorporating bench research into technological interventions. Stroke is a massive public health problem, and in stroke care, immediate assessment and treatment are essential to reduce the risk of death and disability [1, 2]. However, many patients do not receive them due to lack of specialist services. Investigating the aetiology and underlying cause of stroke is key to prevention and rapid recovery. While health care professionals are using the latest technological interventions for the diagnosis and management of the stroke patient, the underlying pathology must be figured out, in order to bridge the gap between diagnosis and long-term care of the stroke patient. At least 20% of ischaemic strokes are caused by carotid artery atherosclerotic plaques [3, 4]. The determination of circulating inflammatory markers have the potential to identify individuals with symptomatic and unstable plaques [1, 5]. Patients with vulnerable plaques usually have a complex disease history and unpredictable road map of recovery.

Plaques are made up of cholesterol, fatty substances, cellular waste products, calcium, and fibrin (a clotting material in the blood). The strength of the fibrous cap is important for plaque stability. Plaques vulnerable to rupture are characterised by a thin fibrous cap and a large lipid-rich necrotic core [4, 6]. Carotid plaque surface morphology can help to indicate plaque vulnerability because both surface irregularity and ulceration have been correlated with stroke [2]. Damage to the arteries' inner walls seems to trigger inflammation and help plaque grow. Stable or asymptomatic plaques are rich in vascular smooth muscle cells (SMC), matrix, and collagen with few inflammatory cells, whereas unstable or symptomatic plaques that are prone to rupture contain few SMCs, more macrophages, and little collagen [5, 7].

Even though there are phenomenal gains in the clinical management of patients with symptomatic carotid artery disease, the molecular mechanisms and pathways leading to plaque instability remain poorly established. Identification of the molecular markers of plaque instability along with signalling mechanisms may help in providing alternatives to surgical treatment and prevention of stroke. Cathepsin L (CTSL) is an important lysosomal endopeptidase enzyme and is involved in the initiation of protein degradation. CTSL is one of the most potent elastases and collagenases [1, 6]. It is normally absent or minimally expressed in tissues including arteries. However, it is overexpressed in atherosclerotic lesions and CTSL expression in vascular cell types found CTSL, to be regulated by pro-inflammatory cytokines in these lesions (Figure 1).

A pilot study consisting of quantitative immunohistochemical analysis of human carotid atherosclerotic lesions was conducted on human

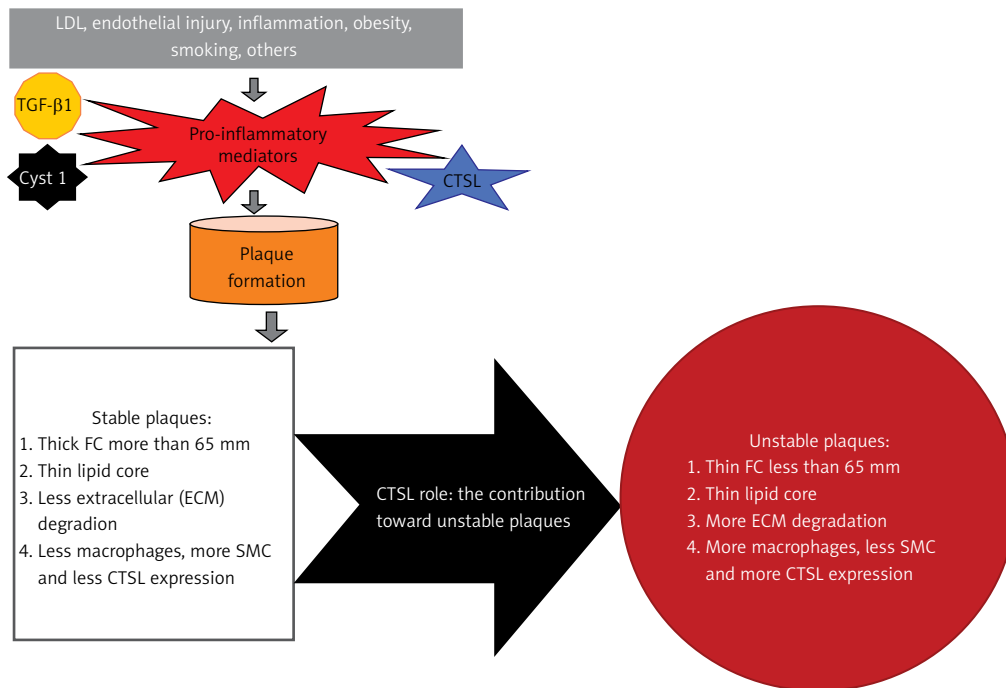


Figure 1. Investigate cathepsin L (CTSL) contribution toward the road map of carotid artery plaque instability

carotid endarterectomy tissues collected anonymously. Plaques were marked as clinically asymptomatic (A) and symptomatic (S) male and female patients, aged between 50 and 75 years. The protein expression of CTSL in S (unstable) plaques compared to A (stable) plaques was analysed by double immunofluorescence. The fibrous cap and necrotic core were assessed by morphometric analysis.

Fibrous cap in S lesions were less than 65 μm and the necrotic core was thicker in symptomatic compared to asymptomatic plaques ($n = 10$) ($S = 52 \pm 19 \mu\text{m}$ vs. $A = 78 \pm 24 \mu\text{m}$, $p < 0.01$). Thin fibrous cap was defined by Virmani *et al.* as one that is less than 65 μm thick, which was measured in our findings. Our initial findings through immunofluorescence studies showed increased expression of CTSL in symptomatic plaques (see supplementary data file). The increased expression of CTSL in S plaques validates the potential role of CTSL in plaque instability and needs further investigation. Cystatin C and transforming growth factor $\beta 1$ (TGF- $\beta 1$) showed expression in A plaques, while CTSL expression is reduced in these plaques.

Cathepsin activity is shown to be involved in inflammation and the degradation of the extracellular matrix (ECM) in the fibrous cap, leading to the destabilisation of the plaque [6, 7]. Cathepsins degrade elastin, collagen, fibronectin, and laminin, and these proteases serve as potential markers for plaque inflammation and vulnerability [5, 7]. CTSL is an important lysosomal endopeptidase, which is involved in the initiation

of protein degradation. CTSL is one of the most potent collagenases and elastases and is implicated in the progression of atherosclerotic plaque establishment, including the necrotic core formation and accumulation of monocytes and macrophages [7]. CTSL is involved in inflammation and degradation of the extracellular matrix in the fibrous cap, causing destabilisation of the plaque. Cystatin C, the endogenous inhibitor of CTSL is normally present in arteries while cathepsin L is not expressed in normal carotid arteries [6]. Significantly lower blood levels of TGF- $\beta 1$ are detected in patients with atherosclerosis; paradoxically, studies indicate that TGF- $\beta 1$ increases SMC cystatin C secretion [6, 8]. The imbalance in the expression between CTSL and their inhibitor Cyst C, along with TGF- $\beta 1$, may favour proteolysis of ECM, leading to the pathogenesis of carotid artery disease and atherosclerosis [7, 8]. Therefore, the concentration of circulating levels of CTSL and their endogenous inhibitor Cyst C could be considered useful as a biomarker and indicator of carotid artery stenosis. Despite previous studies, at present it is still unclear how CTSL plays a role in the development of atherosclerotic plaque instability as well as plaque rupture and necrotic core formation [7].

In conclusion, even though the studies are ongoing, we are still gaining an understanding of the pathogenesis of CTSL interaction with cystatin-C and TGF- $\beta 1$ and its relationship with carotid artery plaques in the hope that this could provide a novel therapy for plaque stabilisation. Monitoring circulating levels of CTSL, cystatin C, and

TGF- β 1 as biomarkers for vulnerable plaques is a unique and innovative future possibility to identify patients with a histologically unstable plaque. In patients with unstable plaques and carotid stenosis the risk of stroke is highest in the first few days and is low in asymptomatic patients with stable plaques [9, 10]. In addition to biomarkers, technological interventions using accessible imaging technology help in identification of patients with a higher or lower likelihood of an unstable carotid plaque (on histology) [10]. Because “time and tide wait for none”, the identification of plaque vulnerability and timely intervention is essential for the patient’s survival and recovery.

Acknowledgments

The research was made possible by the valuable insight and guidance of Dr. Devendra Agrawal; William J. Hunter, MD; the Faculty and Staff of the Clinical Translational Science Department, School of Medicine, Creighton University; Dr. Yiannis S. Chatzizisis (UNMC) and Dr. Sara Myers, Department of Biomechanics, University of Nebraska.

This work was supported by research grant R01HL144125 to DK Agrawal from the NHLBI-NIH, USA.

Conflict of interest

The authors declare no conflict of interest.

References

1. Bashir A, Bashir K, Hunter W, Agrawal D. Cathepsin L expression in the carotid arteries of atherosclerotic swine. *Arch Med Sci Atheroscler Dis* 2019; 4: 264-7.
2. Skagen K, Skjelland M, Zamani M, Russell D. Unstable carotid artery plaque: new insights and controversies in diagnostics and treatment. *Croatian Med J* 2016; 57: 311-20.
3. Benjamin EJ, Blaha MJ, Chiuve SE, et al. Heart disease and stroke statistics-2017 update: a report from the American Heart Association. *Circulation* 2017; 135: e146-603.
4. Virmani R, Kolodgie FD, Burke AP, Farb A, Schwartz SM. Lessons from sudden coronary death: a comprehensive morphological classification scheme for atherosclerotic lesions. *Arterioscler Thromb Vasc Biol* 2000; 20: 1262-75.
5. Liu Y, Li X, Peng D, et al. Usefulness of serum cathepsin L as an independent biomarker in patients with coronary heart disease. *Am J Cardiol* 2009; 103: 476-81.
6. Liu J, Sukhova GK, Sun JS, Xu WH, Libby P, Shi GP. Lysosomal cysteine proteases in atherosclerosis. *Arterioscler Thromb Vasc Biol* 2004; 24: 1359-66.
7. Li W, Kornmark L, Jonasson L, Forssell C, Yuan XM. Cathepsin L is significantly associated with apoptosis and plaque destabilization in human atherosclerosis. *Atherosclerosis* 2009; 202: 92-102.
8. Cipollone F, Fazia M, Mincione G, et al. Increased expression of transforming growth factor-beta1 as a stabilizing factor in human atherosclerotic plaques. *Stroke* 2004; 35: 2253-7.
9. Salem MK, Bown MJ, Sayers RD, et al. Identification of patients with a histologically unstable carotid plaque using ultrasonic plaque image analysis. *Eur J Vasc Endovasc Surg* 2014; 48: 118-25.
10. Chang P, Prabhakaran S. Recent advances in the management of acute ischemic stroke. *F1000Research* 2017; 6: 484.

Data supplement file

Methodology supplement

This research was carried out with the approval of the Institutional Review Board of Creighton University as an exempt research protocol because the carotid endarterectomy specimens were truly anonymised. No information was obtained that could identify the subjects from whom the specimens were obtained. Patients in A (asymptomatic) stable and S (symptomatic) unstable groups were aged between 50 and 75 years and included both male and females of any ethnic origin, who met the guidelines of the American Heart Association. The plaques were clinically classified as symptomatic or asymptomatic by the surgeon, based on history and clinical evaluation of the patients. The symptoms included hemispheric transient ischaemic attacks, amaurosis fugax, or stroke.

Data collection: The specimens were collected in the University of Wisconsin solution and transported to the laboratory as part of the project. A total of 10 symptomatic plaques and 10 asymptomatic plaques were analysed for the study ($n = 10$).

Carotid arteries were fixed in 10% neutral buffered formalin, sectioned serially at 3–4 mm thickness and submitted for paraffin embedding. Histologic sections were cut at 6 μm , mounted

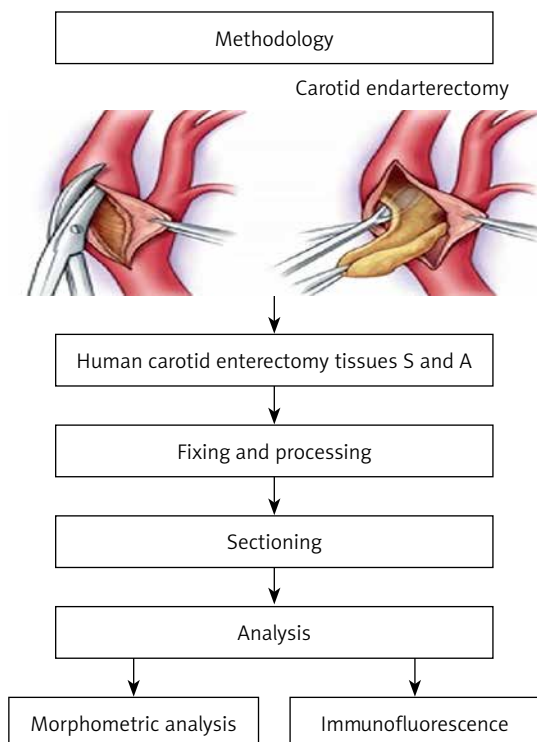
on charged slides, and stained with haematoxylin-eosin (H&E), trichome, and Movat's pentachrome stain.

Analysis: morphometric thickness was measured using an Olympus Slide Scanner microscope (Olympus VS120) and using Image-pro software for analysis.

Immunofluorescence: labelled specimens were examined by confocal microscopy using an Olympus Virtual Slide Scanner microscope (Olympus VS120). Negative controls were incubated with isotype-matched, non-immune IgG. After washing with PBS, the slides were stained with DAPI, (4,6-diamidino-2-phenylindole), and the immunofluorescence was observed in an Olympus inverted fluorescent microscope. DAPI, FITC (green), and TRITC (red) filters were used. The average fluorescence intensity was quantified in the samples using Image-Pro software and OlyVia 2.9 Desktop software.

Reuse potential: all data remain in the central core imaging facility (Creighton University) and can be reused if needed to compare imaging and IF intensity between CTSL, cystatin C, and TGF β 1. Hand E images of carotid arteries help to understand the histology of the tissues, and comparisons to IF images are made easier.

Differences between the two plaque groups were analysed by Student's *t*-test. Data were expressed as percentage or mean \pm SD. Statistical differences between both groups were calculated. All calculations were performed using IBM SPSS version 26 software. A probability value of $p < 0.05$ was considered statistically significant.



Supplementary Figure S1. Material and methods stepwise schematic

Experimental design, material and methods

Study subjects

The specimens were collected in the University of Wisconsin solution and transported to the laboratory as part of the project. A total of 10 symptomatic plaques and 10 asymptomatic plaques were analysed for the study ($n = 10$).

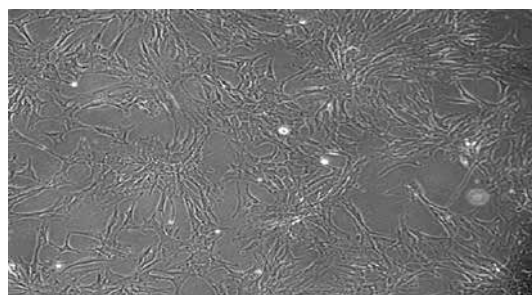
Histological preparation

Carotid arteries were fixed in 10% neutral buffered formalin, sectioned serially at 3–4 mm thickness, and submitted for paraffin embedding. Histologic sections were cut at 6 μm , mounted on charged slides, and stained with haematoxylin-eosin (H&E), trichome, and Movat's pentachrome stain. Thickness was measured using an Olympus Slide Scanner microscope (Olympus VS120), and using Image-pro software for analysis.

Immunohistochemistry

Human endarterectomy specimens were analysed as described below (Supplementary Figure S1).

Immunohistochemistry was carried out using rabbit anti-human CTSL (Sino biological), mouse anti-human Cyst C (Novus Biological), anti-TGF-B1(Novus Biological), anti-CD68 antibody (Santa Cruz Biotechnology), and α -actin (Abcam). The tissue sections were incubated with either mouse monoclonal anti-CD68, anti- α smooth muscle actin (for identification of macrophages and α actin for smooth muscle cells), and anti CTSL antibody alone or in combination to examine the colocalisation of CD68 and CTSL immunopositivity. Sections were also incubated with primary antibody anti-TGF- β 1, anti- α smooth muscle actin, anti-CD68, and matching secondary antibodies 594 (red) or green 488 (anti- α smooth muscle actin, anti-CD68). The tissue sections were incubated with cystatin C alone or double stained with CTSL and TGF B1 antibodies. Omission of primary antibodies and staining with isotype-matched control IgG served as negative controls. Labelled specimens were examined by confocal microscopy using an Olympus Virtual Slide Scanner microscope (Olympus VS120). Negative controls were incubated with isotype-matched, non-immune IgG. After washing with PBS, the slides were stained with DAPI, (4,6-diamidino-2-phenylindole), and the immunofluorescence was observed in an Olympus inverted fluorescent microscope. DAPI, FITC (green), and TRITC (red) filters were used. The average fluorescence intensity was quantified in the samples using Image-Pro software and Oly-Via 2.9 Desktop software.



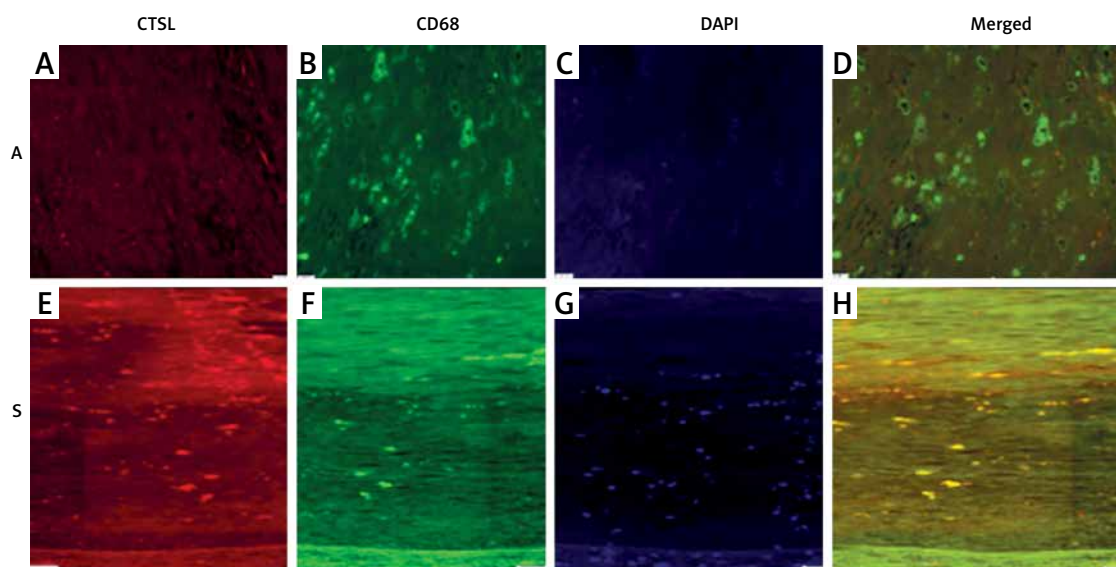
Supplementary Figure S2. SMC treated with CTSL obtained via microscope and image analysis

Antibodies used

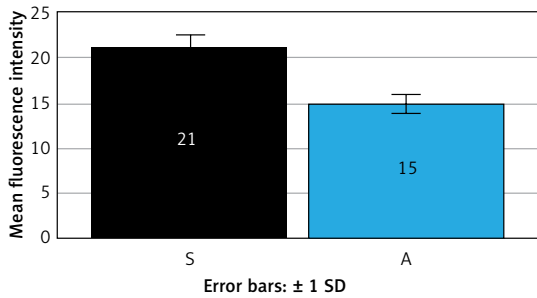
1. Rabbit anti-human CTSL (Sino biological)
2. Mouse anti-human Cyst C (Novus Biological) Manufacturers details found at https://www.novusbio.com/products/cystatin-c-antibody-197820_mab11962.
3. Anti-TGF-B1(Novus Biological) Dilution: Immunohistochemistry 1 : 10–1 : 500 (https://www.novusbio.com/products/tgf-beta-1-antibody_nbp1-80289).
4. Anti-CD68 antibody (Santa Cruz Biotechnology).
5. Anti-alpha-actin (Abcam).

Cell culture from carotid SMC

SMCs were prepared from carotid plaques by an established method developed by the CTS department. After gently scraping endothelial and adventitial layers, the medial layer was homogenised, washed in serum-free DMEM (Gibco



Supplementary Figure S3. Co-localisation of CTSL and CD68 in carotid plaques. Representative immunofluorescence images of cathepsin L (CTSL) (red) and macrophages (CD68) (green) expression as visualised by dual immunofluorescence in carotid plaque sections of asymptomatic (A) (A–D) and symptomatic (S) plaques (H). A, E – CTSL (red); B, F – CD68 (green); C, G – nuclei labelled with DAPI (4,6-diamidino-2-phenylindole); D, H – merged immunopositivity to both CTSL and CD68 in S and A carotid plaques showing greater co-localisation of CTSL in symptomatic (S) plaques ($n = 10$)



Supplementary Figure S4. Quantification of the mean fluorescence intensity of CD68 and CTSL in symptomatic and asymptomatic plaques coimmunostained with CTSL S – symptomatic plaques, A – asymptomatic plaques

Immunofluorescence data

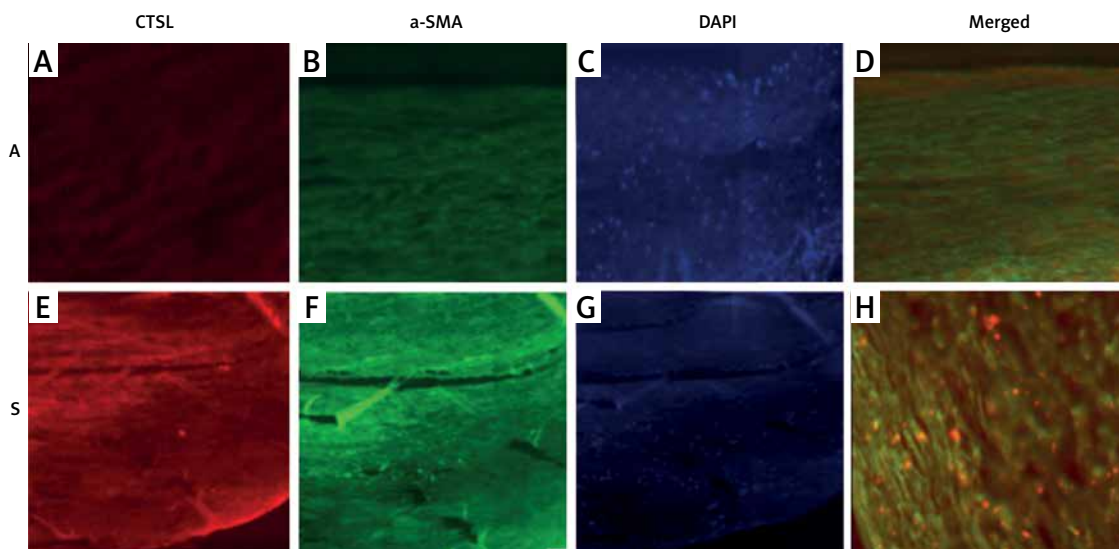
Co-localisation of CTSL and CD68 in carotid plaques (Supplementary Figures S3 and S4)

Co-localisation of CTSL and α -actin SMA in carotid plaques (Supplementary Figure S5)

There is greater expression of CTSL and colocalisation of both actin and CTSL; however, the number of SMC maybe less in symptomatic plaque, as shown by the decrease in mean thickness of the fibrous cap, in S compared to A (Supplementary Table S1).

BRL, Grand island, NY), and digested with 0.025% trypsin for 30 min at 37°C followed by 0.1% collagenase (Sigma, St. Louis, MO) digestion for 3 h. The pellet was suspended in smooth muscle cell medium (ScienCell, Carlsbad, CA) and seeded on to 25 cm² culture flasks and maintained at 37°C and 5% CO₂. The cells from the second to the fifth passages were used. The phenotype and the homogeneity of isolated smooth muscle cells (SMCs) was confirmed by positive staining for smooth muscle α -actin and caldesmon. Once the cells were confluent, they were treated with CTSL, TGFB1, and cystatin C overnight.

SMC treated with CTSL obtained via microscope and image analysis (Supplementary Figure S2).



Supplementary Figure S5. Representative immunofluorescence images of cathepsin L (CTSL) (red) α -smooth muscle actin (α -SMA) (green) expression as visualised by dual immunofluorescence in carotid plaque sections of asymptomatic (A) (A–D) and symptomatic (S) (E–H). A, E – CTSL (red); B, F – actin (α -SMA) (green); C, G – nuclei labelled with DAPI (4,6-diamidino-2-phenylindole); D, H – merged immunopositivity to both CTSL and A in S and A carotid plaques showing greater co-localisation of CTSL and macrophages in symptomatic (S) plaques. Scale bar = 100 μ m for all images (n = 10)

Supplementary Table S1. Raw data for SPSS calculation of mean IF intensity comparison between S and A plaques and colocalisation with α -actin and CTSL

Sample ID unstable symptomatic (S)	No. of α -actin +ve cells in 100 μ m	Sample ID stable asymptomatic (A)	No. of α -actin +ve SMC in 100 μ m
S56	22	A71	16
S95	22	A55	15
S85	23	A64	15
S39	21	A75	14
S89	20	A87	15
S82	22	A59	16
S91	19	A99	15
S92	21	A88	14
S86	22	A66	15
S57	22	A76	16